

Key Points

- We employ a heart team approach in complex coronary cases where the patient consults with a cardiologist, cardiothoracic surgeon, and cardiac interventionalist to determine the best course of treatment.
- For patients with comorbidities, including diabetes and extensive multivessel disease, studies have demonstrated CABG surgery is associated with better long-term survival than PCI.
- At The Mount Sinai Hospital, we have been recommending surgery for patients with complex CAD, and 60 percent of patients have complied with that recommendation.
- We continue to participate in studies to ensure we pursue the best outcomes for every patient.



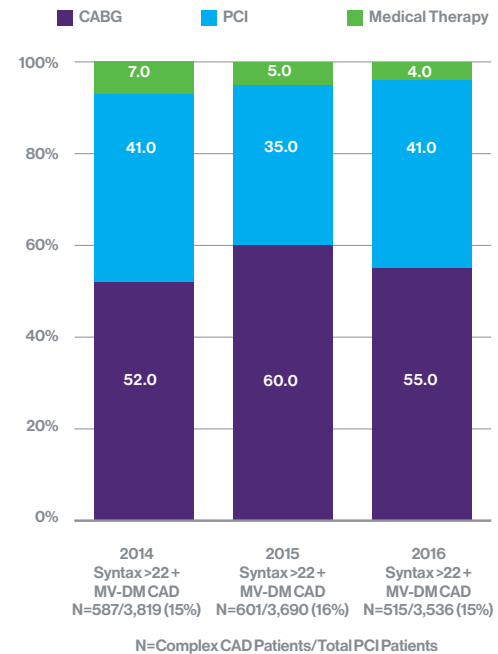To view two prerecorded cases featuring protected high risk and bifurcation PCI, scan the QR codes above.

Complex High-Risk Percutaneous Coronary Interventions (PCI)

Samin K. Sharma, MD Annapoorna S. Kini, MD

Data from several large, multicenter clinical trials continue to inform our approach to clinical decision making for coronary revascularization. Two major trials of multivessel coronary artery disease (CAD), the SYNTAX (SYnergy Between Percutaneous Coronary Intervention with TAXus and Cardiac Surgery) and FREEDOM (Future Revascularization Evaluation in Patients with Diabetes Mellitus: Optimal Management of Multivessel Disease) trials, have established a definite role for coronary artery bypass surgery (CABG), over percutaneous coronary intervention (PCI) with low long-term mortality and myocardial infarction (MI) but higher stroke rates compared to PCI. The SYNTAX trial employed a novel grading tool, known as the SYNTAX Score, to assess the complexity of CAD based on several anatomical factors.

Complex CAD (High SYNTAX Score and MV Diabetes) at Mount Sinai Hospital



Patients with a high SYNTAX Score (>32) were shown to have better five-year survival rates after CABG than after PCI. Ultimately, the decision to either have surgery or PCI lies with the patient and his or her family, after consultation with the heart team, which includes a cardiologist, cardiothoracic surgeon, and cardiac interventionalist. Many patients with complex CAD choose revascularization with PCI, due to lower short-term complications and relative ease of recovery compared with surgery. Data collected over the last several years at The Mount Sinai Hospital reveal that a majority of our patients with complex CAD complied with recommendations to have CABG surgery. Based on this evidence, there is an increasing tendency at The Mount Sinai Hospital toward recommending surgery for patients with more complex CAD.



PATIENT: Charanjit Singh, 53-year-old male

DIAGNOSIS: Three-vessel CAD with 2 CTOs

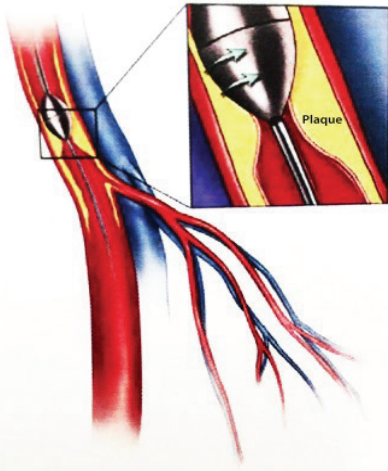
TREATMENT: PCI including PCTA and placement of five DES

“Now I feel perfect, like I’m even younger—maybe even 16 years old.”

“Although I’m quite young, I had visited so many hospitals for what was found to be blockages in my arteries. Everyone wanted to do a bypass surgery, but at my age, I knew that I didn’t want to face a big surgery like that if it was avoidable. One of my doctors recommended seeing Dr. Sharma. He said, ‘He is the best doctor in the world and if he can’t help you, no one can.’ He was absolutely right. When I went to meet Dr. Sharma, he saw me in the waiting room and couldn’t believe

that I was a patient. He said he would place my stents right away, that very same day. He was done within 45 minutes—five stents—and I had no pain at all. When Dr. Sharma went to tell my family the good news, they were all dancing! Now I feel perfect, like I’m even younger—maybe even 16 years old—and after each day at work, I still feel fresh. Believe me, he’s the #1 doctor in the world, and he’s very special, not just for me, but for everyone.”

Rotational Atherectomy



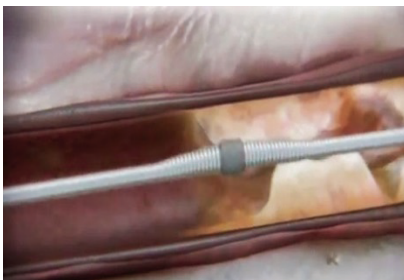Since the conclusion of the SYNTAX and FREEDOM trials in 2008-2010, in which patients in the PCI arm were treated with the sirolimus- or paclitaxel-eluting stent (first generation drug-eluting stents (DES)), a newer generation of DES systems have arrived in clinical practice. These newer stents, such as the zotarolimus-eluting stent and the everolimus-eluting stent, have thinner struts and are associated with better healing causing lower restenosis and lower thrombosis. Data from a registry-based study of 34,819 patients with multivessel CAD revealed that patients who underwent PCI with an everolimus-eluting stent had a lower short-term risk of death and stroke compared with those who had CABG surgery. However, PCI was associated with a higher risk of repeat revascularization and myocardial infarction (MI) and no difference in death at long term. The latest generation of coronary stents incorporates biodegradable polymers that may even further reduce late thrombosis. The trial of bioabsorbable vascular scaffold (BVS) ABSORB II, comparing BVS with Xience DES, has shown higher MI and stent thrombosis at three-year follow-up. As a result, BVS use is kept at a minimum in our interventional practice. Another recent trial comparing Xience

DES with CABG in unprotected left main disease (EXCEL Trial) with Syntax Score <32 has shown equal results after both modes of revascularization. Additional studies that take these design changes into account, combined with the use of more advanced imaging modalities before and during procedures, may tip the balance in favor of recommending PCI as first-line therapy for more patients with moderate to severe CAD.

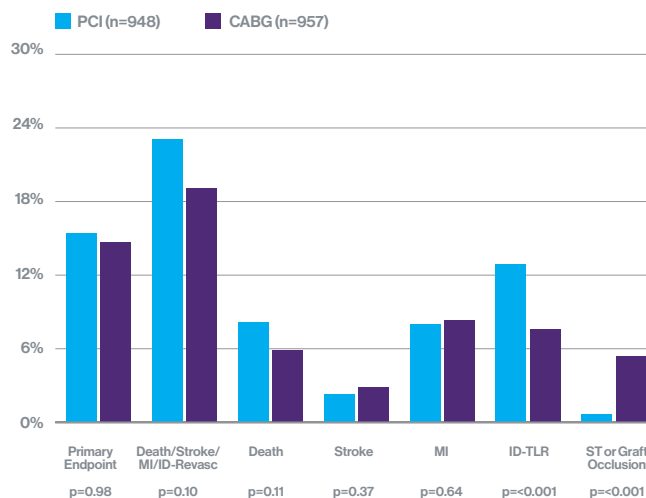
In addition to expertise in treating multivessel CAD with PCI, our Catheterization Laboratory also serves as a tertiary center for complex coronary intervention (bifurcation, calcified, left main, CTO, and/or vein graft lesions) and patients with low ejection fraction (LVEF <35 percent). We use a variety of adjunct interventional techniques in these complex coronary cases, such as atherectomy (for calcified lesions, 20 percent) and thrombectomy/distal protection devices (for thrombotic and vein graft lesions, in 3 percent).

In a small number of complex lesion patients (=5 percent of PCI) with reduced ejection fraction (LVEF <35 percent) we use LV assist devices such as IABP, Impella or ECMO to safely and dependably perform these high-risk PCI (protected PCI).

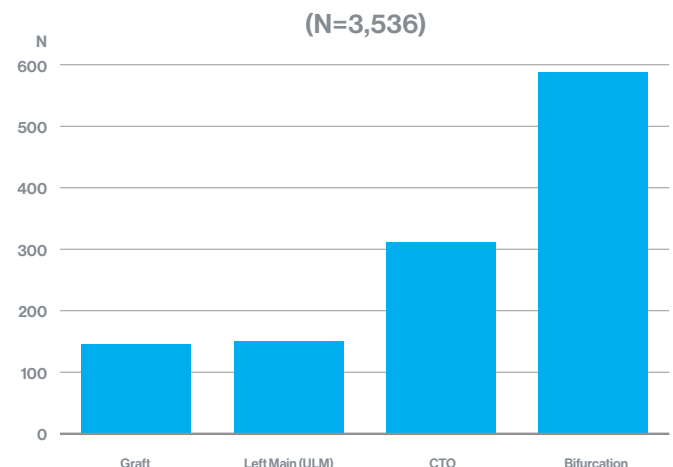
Orbital Atherectomy



EXCEL Trial: Primary and Secondary Clinical Endpoints



Complex Coronary Intervention in 2016 at Mount Sinai Hospital

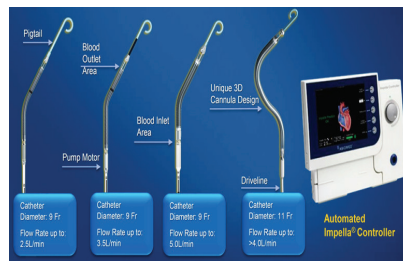

LV Assist Devices

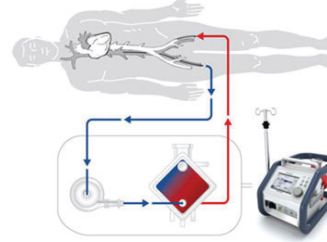
Intra-Aortic Balloon Pump (IABP)



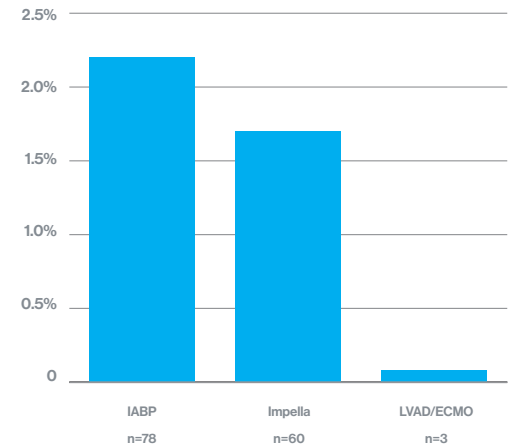
Impella Devices



Extracorporeal Membrane Oxygenation (ECMO)



High Risk PCI With LV Support in 2016 at Mount Sinai Hospital (N= 3,536)



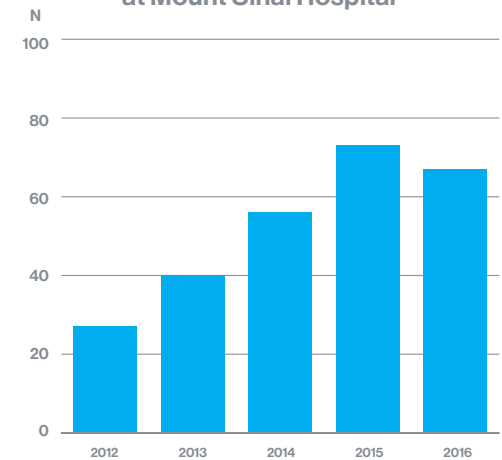
Intravascular Brachytherapy (IVBT) for Recurrent DES In-Stent Restenosis

Patients presenting with recurrent in-stent restenosis (ISR) of DES with more than two layers of stents are appropriate cases for IVBT using the Beta-Cath™ System to reduce subsequent restenosis. Our IVBT data over the last five years have shown excellent acute outcomes with <1 percent major complications, no need for implantation of another stent and long-term restenosis of 25 percent (compared to 55 percent in comparable recurrent DES ISR without IVBT).

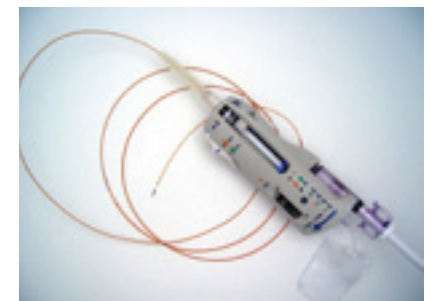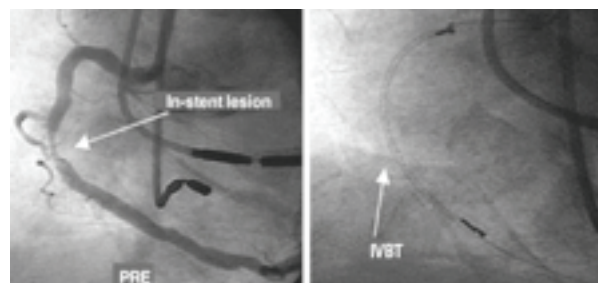
References:

1. Coronary artery bypass graft surgery versus percutaneous coronary intervention in patients with three-vessel disease and left main coronary disease: 5-year follow-up of the randomized clinical SYNTAX trial, *Lancet* 2013;381:629.
2. Strategies for multivessel revascularization in patients with diabetes (FREEDOM trial), *N Engl J Med* 2012;367:2375.
3. Comparison of an everolimus-eluting bioresorbable scaffold with an everolimus-eluting metallic stent for the treatment of coronary artery stenosis (ABSORB II): a 3-year, randomized, controlled, single-blind, multicentre clinical trial, *Lancet* 2016;388:2479.
4. Everolimus-eluting stents or bypass surgery for left main coronary artery disease (EXCEL trial), *N Engl J Med* 2016;375:2223.

Volume of IVBT Procedures at Mount Sinai Hospital



Intravascular Brachytherapy Treatment



Novoste™ Beta-Cath™ 3.5F System